

Département de
Gynécologie-Obstétrique
de l'Université de Liège



XVII^{èmes} Journées
Liégeoises de
Gynécologie-Obstétrique

BACK TO THE FUTURE



Recommandations de l'IS-PAS pour la gestion du Placenta Accreta Spectrum

FREDERIC CHANTRAINE - MD PHD

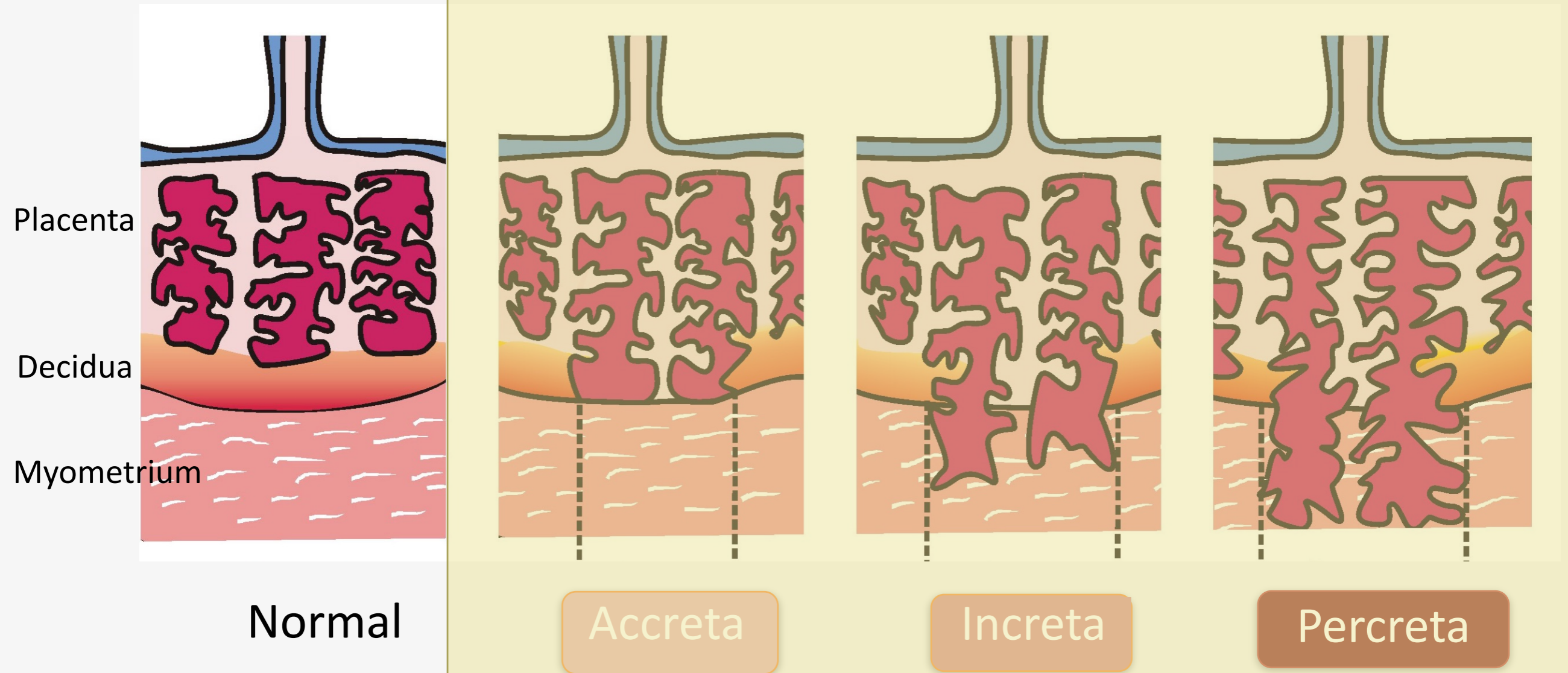
Placenta percreta

AIP

Abnormally Invasive Placenta

PAS

Placenta accreta spectrum



REVIEW ARTICLE

Obstetrics

WILEY



FIGO classification for the clinical diagnosis of placenta accreta spectrum disorders^{☆,★}

Eric Jauniaux^{1,*} | Diogo Ayres-de-Campos² | Jens Langhoff-Roos³ | Karin A. Fox⁴ |
Sally Collins^{5,6} | FIGO Placenta Accreta Diagnosis and Management Expert Consensus Panel^a

Accepted: 14 January 2019

Classification „clinique“

- **Grade 1:** Abnormally adherent placenta (placenta adherents or creta)
- **Grade 2:** Abnormally invasive placenta (Increta)
- **Grade 3:** Abnormally invasive placenta (Percreta)
 - **Grade 3a:** limited to the uterine serosa
 - **Grade 3b:** with urinary bladder invasion
 - **Grade 3c:** with invasion of other pelvic tissue/organs

Classification „pathologie“

- **PAS Grade 1** – non invasive
- **PAS Grade 2** – superficial invasion
- **PAS Grade 3A** – deep invasion
- **PAS Grade 3D** – deep invasion with disruption of the serosa
- **PAS Grade 3E** – deep invasion with adherent extrauterine structures



Recommendations

ULTRASOUND
in Obstetrics & Gynecology



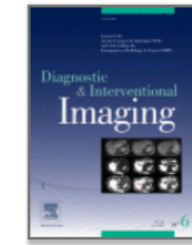Editorial |  Free Access


Proposal for standardizing diagnostic and interventional imaging of abnormally-invasive placentation



Diagnostic and Interventional Imaging

Volume 100, Issue 6, June 2019, Pages 319-325



S. L. Collins , A. Ashcroft
Chantraine, on behalf of t

Recommendations
Obstetric imaging

A proposal for standardizing diagnostic and interventional imaging of abnormally-invasive placentation




American Journal of Obstetrics and Gynecology

Available online 5 March 2019

In Press, Accepted Manuscript 



O. Morel ^a , S.L. Collins ^t
Langhoff-Roos ^g, P. Soyer ^{c, d}
(IS-AIP)

Special Report

Evidence-based guidelines for the management of abnormally-invasive placenta (AIP): recommendations from the International Society for AIP

Sally L. Collins ^{1, 2} , Bahrin Alemdar ³, Heleen J. van Beekhuizen ⁴, Charline Bertholdt ⁵, Thorsten Braun ⁶, Pavel Calda ⁷, Pierre Delorme ⁸, Johannes J. Duvekot ⁹, Lene Gronbeck ¹⁰, Gilles Kayem ¹¹, Jens Langhoff-Roos ¹⁰, Louis Marcellin ¹², Pasquale Martinelli ¹³, Olivier Morel ⁵, Mina Mhallem ¹⁴, Maddalena Morlando ^{13, 15}, Lone N. Noergaard ¹⁰, Andreas Nonnenmacher ⁶ ... Frederic Chantraine ¹⁷



American Journal of Obstetrics and Gynecology

Available online 5 March 2019

In Press, Accepted Manuscript 



Special Report

Evidence-based guidelines for the management of abnormally-invasive placenta (AIP): recommendations from the International Society for AIP

Sally L. Collins^{1, 2}  , Bahrin Alemdar³, Heleen J. van Beekhuizen⁴, Charline Bertholdt⁵, Thorsten Braun⁶, Pavel Calda⁷, Pierre Delorme⁸, Johannes J. Duvekot⁹, Lene Gronbeck¹⁰, Gilles Kayem¹¹, Jens Langhoff-Roos¹⁰, Louis Marcellin¹², Pasquale Martinelli¹³, Olivier Morel⁵, Mina Mhallem¹⁴, Maddalena Morlando^{13, 15}, Lone N. Noergaard¹⁰, Andreas Nonnenmacher⁶ ... Frederic Chantraine¹⁷

Oxford Centre for Evidence-based Medicine – Levels of Evidence (March 2009)

- Level 1: SR of RCT, RCT
- Level 2: SR of cohort studies, individual cohort studies
- Level 3: SR of case-control studies, individual case-control study
- Level 4: case series
- Level 5: expert opinion

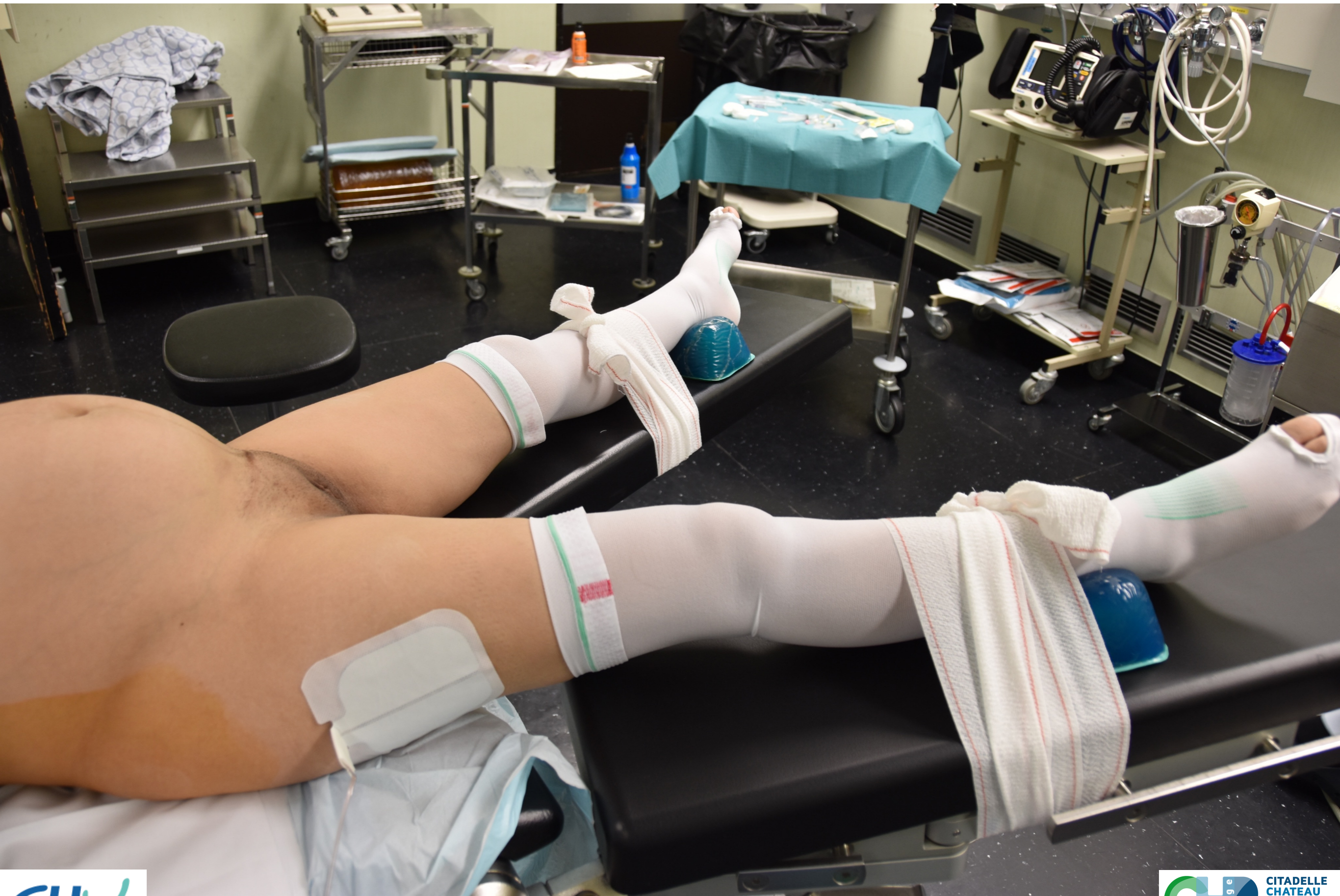Grades of recommendation

- **A** consistent level 1 studies
- **B** consistent level 2 or 3 studies or extrapolation from level 1
- **C** level 4 studies or extrapolation from level 2 or 3
- **D** level 5 evidence

Existe-t-il une position maternelle optimale pour la césarienne des femmes ayant une suspicion anténatal de PAS?

- There are no publications which specifically address the question of maternal position for surgery for women with PAS. Therefore, the IS-PAS recommendation is based on consensus opinion (level 5 evidence) and is as follows:

- *When hysterectomy is either planned or likely, the woman should be placed in a position where the vagina is potentially accessible (such as lithotomy or legs straight on the operating table but parted) to facilitate manipulation of the cervix, if required to assist the hysterectomy.*
- *This will also allow easier assessment of any blood lost vaginally*
- *(Grade D recommendation)*



À quelle age gestationnel les femmes avec un PAS doivent-elles accoucher ?

- *The timing of delivery should be tailored to each unique set of circumstances and based on the individual woman's risk of emergent delivery.*
- *To reduce the risk of neonatal morbidity it is reasonable to continue expectant management until **after 36+0 weeks' gestation** for women with no previous history of pre-term delivery (<36+0 weeks) and who are stable with no vaginal bleeding, PPRROM, or uterine contractions suggestive of pre-term labor.*
- *In the case of women with history of previous pre-term birth, multiple episodes of small amounts of vaginal bleeding, a single episode of a significant amount of vaginal bleeding or PPRROM, planned delivery at **around 34+0 week's gestation** should be considered given the significantly increased risk of emergent delivery*
- *(Grade D recommendation)*

- Développement d'un CRF papier entre 2012-2014
- Mise en place d'une base de données en ligne: FetView, Zeitgeist Health SE
- 14 centres européens et un centre non européen (États-Unis) ont fourni des cas traités rétrospectivement entre 2008 et 2014 et prospectivement de 2014 à 2019.
- L'approbation du comité d'éthique/IRB local et les accords d'utilisation des données ont été obtenus conformément aux politiques locales de chaque centre.
- 442 cas analysables

- 329 femmes (74,4%) avaient un antécédent de césarienne
- 375 femmes (84,8%) présentaient un placenta praevia
- Chez 385 femmes (87,1%), le PAS a été diagnostiqué avant la naissance.
- 252 femmes (57%) ont eu une césarienne-hystérectomie avec une ré-opération chez 20 femmes (7,9%) en raison de complications.
- 32 femmes (7,7%) étaient faussement positives lors de l'évaluation prénatale.
- Perte de sang plus faible ($p < 0,002$) en 2018-2019 par rapport à 2009-2017, suggérant une courbe d'apprentissage positive

AOGS

AOGS
100 Years
1921-2021

Acta Obstetricia et Gynecologica
Scandinavica

Placenta
Accreta
Spectrum:
Evidence from a
large multinational
database



Editor: Amar Bhide

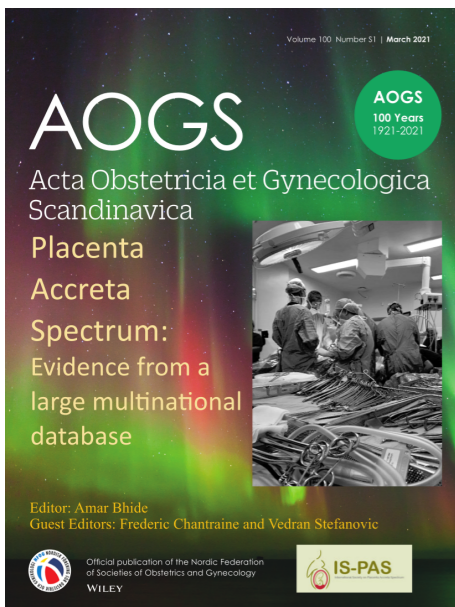
Guest Editors: Frederic Chantraine and Vedran Stefanovic



Official publication of the Nordic Federation
of Societies of Obstetrics and Gynecology

WILEY





Contents

Commentaries

F. Chantraine, V. Stefanovic, T. Braun, P. Calda, P. Martinelli and S. L. Collins **3**
When a rare condition creates a scientific society: The history of the International Society for Placenta Accreta Spectrum (IS-PAS)

T. Braun, H. J. van Beekhuizen, M. Morlando, O. Morel and V. Stefanovic **7**
Developing a database for multicenter evaluation of placenta accreta spectrum

Original Research Articles

H. J. van Beekhuizen, V. Stefanovic, A. Schwickert, W. Henrich, K. A. Fox, M. MHallem Gziri, L. Sentilhes, L. Gronbeck, F. Chantraine, O. Morel, C. Bertholdt, T. Braun, M. J. Rijken and J. J. Duvekot **12**
A multicenter observational survey of management strategies in 442 pregnancies with suspected placenta accreta spectrum

O. Morel, H. J. van Beekhuizen, T. Braun, S. Collins, P. Pateisky, P. Calda, W. Henrich, A. Al Naimi, L. Nikoline Norgaardt, K. M. Chalubinski, L. Sentilhes, B. Tutschek, A. Schwickert, V. Stefanovic and C. Bertholdt **21**
Performance of antenatal imaging to predict placenta accreta spectrum degree of severity

A. Schwickert, H. J. van Beekhuizen, C. Bertholdt, K. A. Fox, G. Kayem, O. Morel, M. J. Rijken, V. Stefanovic, G. Strindfors, A. Weichert, K. Weizsaecker and T. Braun **29**
Association of peripartum management and high maternal blood loss at cesarean delivery for placenta accreta spectrum (PAS): A multinational database study

M. Morlando, A. Schwickert, V. Stefanovic, M. M. Gziri, P. Pateisky, K. M. Chalubinski, A. Nonnenmacher, O. Morel, T. Braun, C. Bertholdt, H. J. Van Beekhuizen and S. L. Collins **41**
Maternal and neonatal outcomes in planned versus emergency cesarean delivery for placenta accreta spectrum: A multinational database study

M. C. Vieira, M. J. Rijken, T. Braun, F. Chantraine, O. Morel, A. Schwickert, V. Stefanovic, H. van Beekhuizen and S. L. Collins **50**
The relation between maternal obesity and placenta accreta spectrum: A multinational database study

Received: 17 October 2020 | Revised: 30 January 2021 | Accepted: 5 February 2021

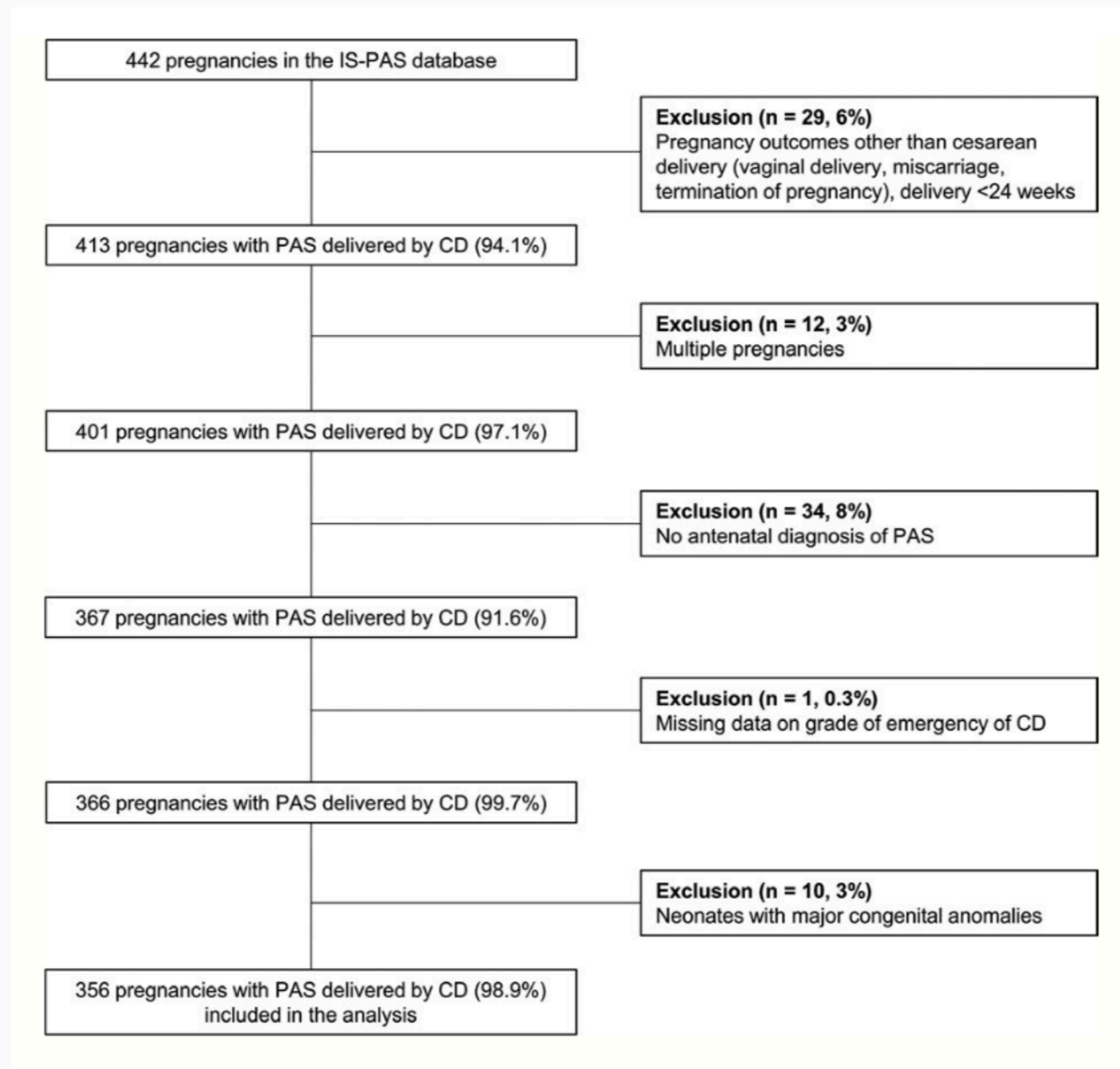
DOI: 10.1111/aogs.14120



ORIGINAL RESEARCH ARTICLE

Maternal and neonatal outcomes in planned versus emergency cesarean delivery for placenta accreta spectrum: A multinational database study

Maddalena Morlando^{1,2}  | Alexander Schwickert³  | Vedran Stefanovic⁴  |
Mina M. Gziri⁵  | Petra Pateisky⁶ | Kinga M. Chalubinski⁶ | Andreas Nonnenmacher³ |
Olivier Morel^{7,8}  | Thorsten Braun^{3,9}  | Charline Bertholdt^{7,8}  |
Heleen J. Van Beekhuizen¹⁰  | Sally L. Collins^{11,12}  | on behalf of the International Society
for Placenta Accreta Spectrum (IS-PAS)*



	Planned delivery (n = 239)	Emergency delivery (n = 117)	P value	Missing data (%)
Antepartum characteristics				
Age ^a	35 (31–38)	34 (31–38)	.66	2 (0.6)
Parity ^a	2 (1–2)	2 (1–3)	.01	0
Previous cesarean sections ^a	1 (1–2)	2 (1–3)	.07	0
Previous D&C ^a	0 (0–1)	0 (0–1)	.51	
Placenta previa ^b	219 (92)	109 (93)	.61	0
Ethnicity ^c			.42	22 (6)
African, Caribbean and African-American	13 (5)	5 (4)		
East Asian	2 (1)	2 (2)		
South Asian	14 (6)	3 (3)		
European, Middle Eastern, and Latin American	193 (81)	102 (87)		
BMI at booking ^a	25.5 (23.2–28.7)	24.6 (22.3–28.3)	.02	17 (5)
Antepartum hemorrhage ^b	67 (28)	77 (66)	<.001	0
Gestational age of first episode of antepartum hemorrhage (weeks) ^a	28 (26–32)	29 (24–33)	.44	0
Maternal outcomes				
Estimated blood loss ^a	2000 (1200–4000)	1550 (1000–3500)	.89	14 (4)
Blood units transfused ^a	2 (0–6)	2 (0–6)	.45	0
Maternal ITU admission ^b	78 (33)	53 (45)	.02	0
Gestational age at delivery (weeks) ^a	36 (35–37)	34 (32–36)	<.001	0
Major maternal morbidity^d				
Renal failure ^c	0 (0)	1 (1)	.33	0
Bowel damage ^c	2 (1)	0 (0)	–	0
Urinary tract damage ^c	2 (1)	1 (1)	–	0
Bladder damage ^b	10 (4)	8 (7)	.31	0
Genitourinary fistula ^c	1 (0.4)	0 (0)	–	0
Cardiac arrest ^c	0 (0)	1 (1)	.33	0
Hemorrhagic shock ^c	1 (0.4)	1 (1)	.55	0
Wound infection ^c	0 (0)	2 (2)	.11	0
Thrombotic event ^c	2 (1)	2 (2)	.60	0
Sepsis ^c	1 (0.4)	0 (0)	–	0

Risk factors for emergency cesarean delivery

	Univariate		Multivariate	
	Crude OR (95% CI)	P values	Adjusted OR (95% CI)	P values
Gravidity	1.3 (1.1–1.5)	.01	1.2 (0.9–1.7)	.16
Parity	1.3 (1.1–1.6)	.01	1.1 (0.8–1.6)	.60
BMI at booking	0.9 (0.9–1.0)	.02	0.9 (0.9–1.0)	.06
Antepartum hemorrhage	5.0 (2.9–8.7)	<.001	4.7 (2.6–8.5)	<.001

Indication for delivery according to PAS grade

	Grade 1 n = 26 (7%)	Grade 2 n = 56 (16%)	Grade 3 n = 58 (16%)	Grade 4 n = 135 (38%)	Grade 5 n = 52 (15%)	Grade 6 n = 29 (8%)	Total (n = 356)	P value
Planned delivery	19 (73)	40 (71)	38 (66)	90 (67)	33 (62)	19 (66)	239 (67)	.35
Emergency delivery	7 (27)	16 (29)	20 (34)	45 (33)	19 (38)	10 (37)	117 (33)	
Bleeding	3 (43)	8 (50)	7 (35)	19 (42)	2 (11)	2 (20)	41 (35)	.03
Labor and other reasons ^a	4 (57)	8 (50)	13 (65)	26 (58)	17 (89)	8 (80)	76 (65)	

Results

	24 ⁺⁰ to 34 ⁺⁰ weeks			34 ⁺¹ to 36 ⁺⁰ weeks			≥36 ⁺¹ weeks		
	Planned	Emergency	p value	Planned	Emergency	P value	Planned	Emergency	p value
Number of cases	27	65		99	33		113	19	
Birthweight in grams ^a	2315 (2143-2552)	1808 (1488-2100)	<.001	2550 (2415-2730)	2620 (2510-2840)	.38	3030 (2670-3305)	2860 (2540-2890)	0.03
5 min APGAR score ^a	9 (8-10)	8 (6-9)	.02	9 (7-10)	9 (7-10)	.40	9 (8-10)	10 (9-10)	0.17
Arterial pH ^a	7.31 (7.30-7.37)	7.30 (7.24-7.33)	.07	7.30 (7.26-7.34)	7.30 (7.26-7.35)	.67	7.29 (7.26-7.31)	7.27 (7.25-7.30)	0.27
Days in NICU ^a	0 (0-6)	12 (0-31)	<.001	0 (0-4)	0 (0-8)	.36	0 (0-0)	0 (0-0)	0.75
Major neonatal morbidities ^b									
Respiratory distress syndrome ^c	1 (6)	4 (24)	.18	11 (24)	3 (15)	.52	9 (17)	0 (0)	0.19
Severe jaundice (requiring phototherapy) ^c	1 (6)	4 (24)	.18	4 (9)	2 (10)	1.00	0 (0)	1 (8)	0.20
Severe infection (e.g. sepsis, meningitis) ^c	0 (0)	0 (0)	n/a	0 (0)	1 (5)	.30	0 (0)	0 (0)	n/a
IVH, NEC, neonatal encephalopathy, exchange transfusion ^c	0 (0)	0 (0)	n/a	0 (0)	0 (0)	n/a	0 (0)	0 (0)	n/a
Neonatal mortality									
Stillbirth	0 (0)	0 (0)	n/a	0 (0)	0 (0)	n/a	0 (0)	0 (0)	n/a
Neonatal death ^c	0 (0)	0 (0)	n/a	0 (0)	1 (5)	.30	0 (0)	0 (0)	n/a

The rate of any major neonatal morbidity:

- 25% at 34+0 weeks
- 19% at 36+0 weeks

- Emergency delivery in a center of excellence for PAS does not appear to increase maternal morbidity, but earlier delivery holds iatrogenic risks of prematurity for the neonate
- The single greatest risk factor for emergency delivery is antenatal hemorrhage.
- Therefore, delivery at $>36+0$ weeks' gestation in women who have not bled and have no risk factors for pre-term birth could be considered.
- However, the findings from the present study should be interpreted with caution, as they are based on highly experienced referral centers for the management of PAS and therefore do not necessarily reflect the possible effect of this kind of delivery strategy in less experienced centers.
- Future research should be focused on the development of an accurate system to identify the women at lower risk of emergency delivery, whose infants might benefit from later delivery with no increase in maternal morbidity.
- *(Grade C recommendation)*








Chercher le PAS



REVIEW ARTICLE

Obstetrics

A simple guide to ultrasound screening for placenta accreta spectrum for improving detection and optimizing management in resource limited settings

Theophilus K. Adu-Bredu¹  | Marcus J. Rijken^{2,3}  | Albaro Jose Nieto-Calvache^{4,5}  |
Vedran Stefanovic⁶  | Rozi Aditya Aryananda⁷  | Karin Anneliese Fox⁸  |
Sally L. Collins^{9,10}  | the International Society of Placenta Accreta SPECTRUM (IS-PAS)
Low- and Middle-Income Countries Working Group

Step 1: Awareness

- Assess risk factors for PAS (*pre-test probability*)
 - **Anterior low-lying (<2 cm from internal os) or placenta previa + previous cesarean delivery/ies**
 - History of uterine surgery or myometrial/endometrial damage

Step 2: Remember it is a spectrum

- Ultrasound signs represent different anatomical features, e.g. neovascularity
- Severity and intra-operative findings vary significantly
- **Each PAS will have different ultrasound signs representing anatomical features unique to that case**

Step 3: Consider the clinical relevance

- **Utero-placental bed**
 - Placental bulge = defect in uterine muscle (PAS or dehiscence) definitely insufficient muscle to contract
 - Myometrial thinning (<1 mm or undetectable) = probably insufficient muscle to contract
 - Loss of “clear zone” = loss of smooth placental surface with probable “fusion” of placenta to uterus
- **Abnormal lacunae**
 - Large, irregular, anechoic areas connecting with the myometrium = destruction of the placental tissue by high pressure “feeder” blood vessels from deep within the uterus (radial/arcuate arteries)
 - *If Doppler is available the feeder vessels can be seen (>10 cm/s)*
- **Neovascularization signs**
 - Bladder wall interruption = presence of tangled mat of new blood vessels between the anterior uterine wall and posterior bladder wall (ultrasound artifacts from vessel walls cause “=” appearance or “scalloping”)
 - *If Doppler is available this is seen as “bridging vessels”*

Examen systématique du placenta:

- Chez chaque patiente
- En cas d'antécédents de chirurgie utérine
- **En cas d'un placenta praevia avec antécédent de césarienne**

Si il ya suspicion de PAS = demander un deuxième avis

Signes échographiques

SUSPECTED ABNORMALLY INVASIVE PLACENTA (AIP)

Ultrasound report

Demographics and Risk Factors

Date: __/__/____ Gestational age: __ weeks __ days

Parity Mode of conception: Spontaneous IVF

Number of previous CS Number of classical CS

Number of previous surgical evacuations (including TOP)

Was Cesarean scar pregnancy suspected/diagnosed in first trimester? Yes No Not known

Previous uterine surgery (e.g. myomectomy, endometrial ablation) Yes No Not known

History of AIP Yes No Not known

Placenta previa on ultrasound

If yes: Anterior placenta previa < 2 cm from internal os Covering internal os

Posterior placenta previa < 2 cm from internal os Covering internal os

Ultrasound Signs

Cervical length (without funnel or placental tissue)	mm		
Grayscale ultrasound parameters and definition	Yes	No	Unsure
Loss of 'clear zone' - Loss, or irregularity, of hypoechoic plane in myometrium underneath placental bed ('clear zone')			
Myometrial thinning - Thinning of myometrium overlying placenta to <1mm or undetectable			
Abnormal placental lacunae - Presence of numerous lacunae including some that are large and irregular, often containing turbulent flow visible on grayscale imaging			
Bladder wall interruption - Loss or interruption of bright bladder wall (hyperechoic band or 'line' between uterine serosa and bladder lumen)			
Placental bulge - Deviation of uterine serosa away from expected plane, caused by abnormal bulge of placental tissue into neighboring organ, typically bladder; uterine serosa appears intact but outline shape is distorted			
Focal exophytic mass - Placental tissue seen breaking through uterine serosa and extending beyond it; most often seen inside filled urinary bladder			
Color Doppler ultrasound parameters and definition	Yes	No	Unsure
Uterovesical hypervascularity - Striking amount of color Doppler signal seen between myometrium and posterior wall of bladder; this sign probably indicates numerous, closely packed, tortuous vessels in that region (demonstrating multidirectional flow and aliasing artifact)			
Subplacental hypervascularity - Striking amount of color Doppler signal seen in placental bed; this sign probably indicates numerous, closely packed, tortuous vessels in that region (demonstrating multidirectional flow and aliasing artifact)			
Bridging vessels - Vessels appearing to extend from placenta, across myometrium and beyond serosa into bladder or other organs; often running perpendicular to myometrium			
Placental lacunae feeder vessels - Vessels with high-velocity blood flow leading from myometrium into placental lacunae, causing turbulence upon entry			
Parametrial involvement	Yes	No	Unsure
- Suspicion of invasion into parametrium			

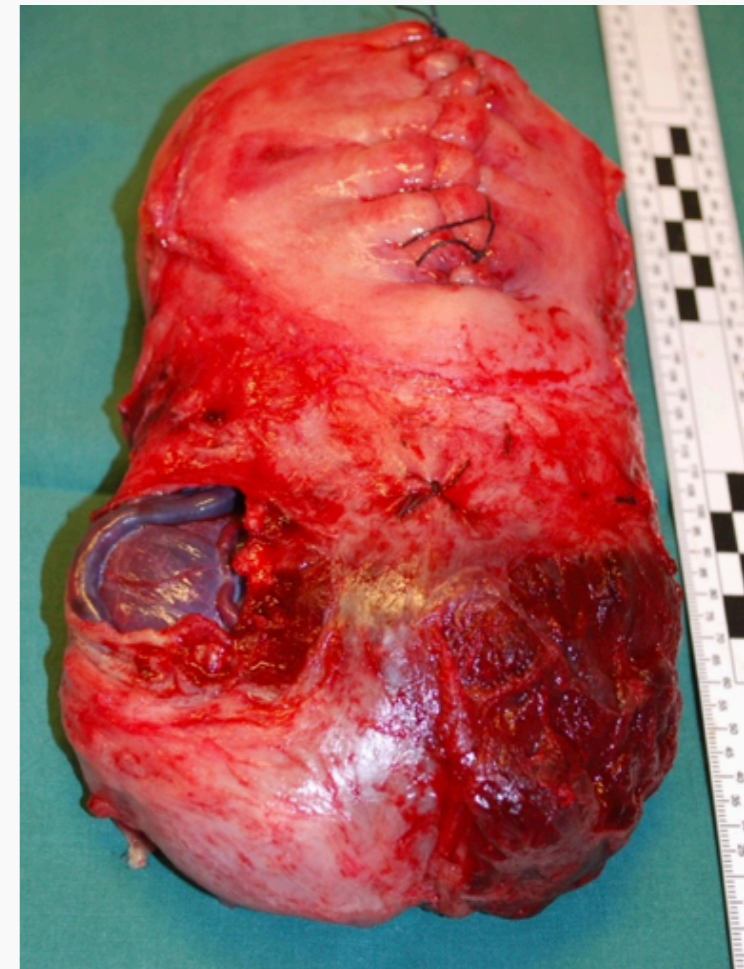
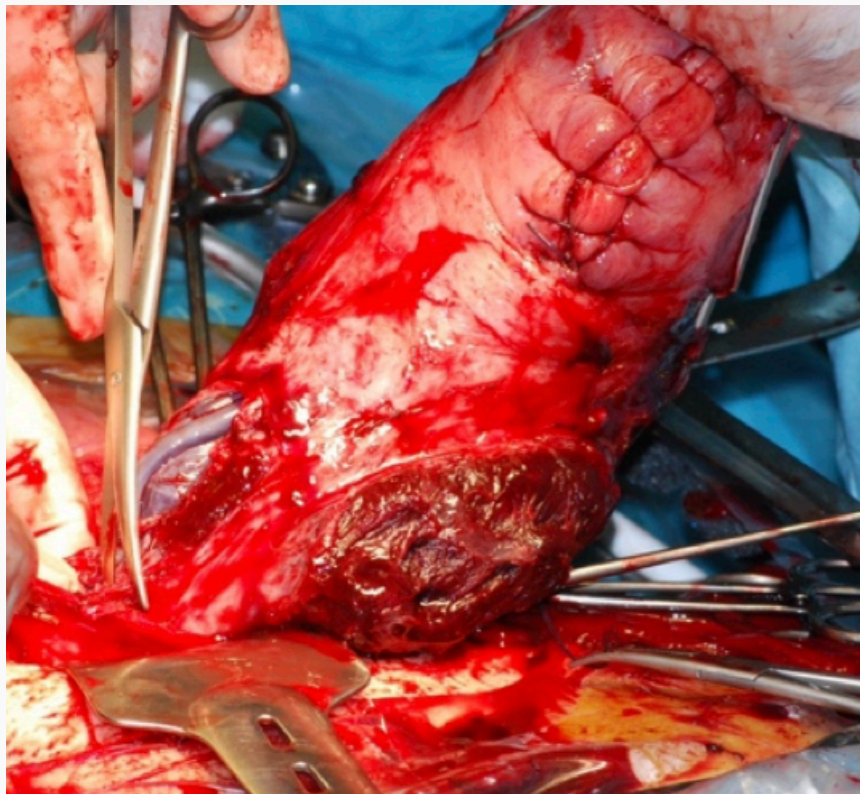
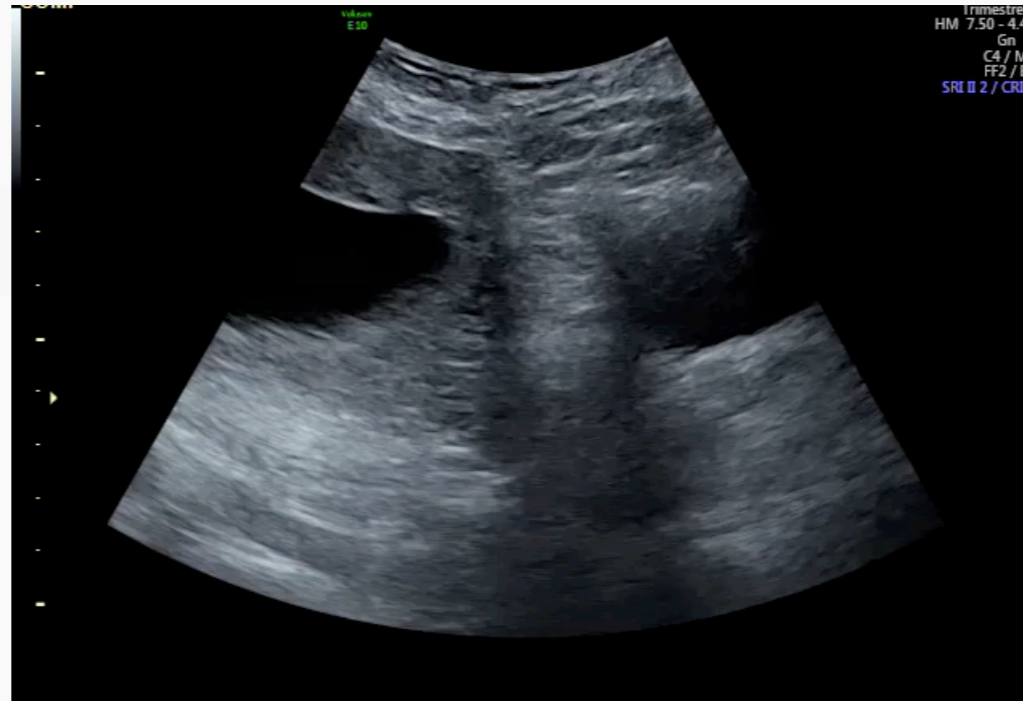
Clinical Significance of Ultrasound Findings

Probability of clinically significant AIP High Intermediate Low

Extent of AIP Focal Diffuse

Cas clinique

- Femme de 30 ans
- G2P1
- 1 césarienne électorive pour siège
- Métrorragies T1
- Echographie à 20+3 SA



MDT

- Éviter la première césarienne
- Le PAS est rare, mais son incidence augmente
- Éviter le sous-diagnostic, mais aussi le sur-diagnostic
- MDT: discussion/réunion prénatale et postnatale
- Collaboration multi-centrique
- Utiliser la classification internationale actuellement acceptée

www.is-pas.org



- HOME
- NEWS
- ABOUT US
- FOR PATIENTS
- GUIDELINES
- PUBLICATIONS-LINKS
- MEMBERSHIP
- LOGIN



For patients

Flyer for download (leaflet): [Czech](#) [English](#) [French](#) [German](#) [Italian](#) [Portuguese](#) [Slovak](#) [Spanish](#) [Polish](#)

